

The information contained herein is not legal advice. Do not act upon this information without seeking legal counsel. If you have questions concerning this presentation, please contact Dennis A. Marks at 312-540-7526 or via dmarks@querrey.com.

©2006 Querrey & Harrow, Ltd. All rights reserved.



Hips and Ankles

Presented for educational purposes by:

Querrey  *Harrow*

Featured Speaker:


John A. Hefferon, M.D.

Co-Medical Director, The Neurologic & Orthopedic Institute of Chicago



Hip Anatomy

- Bone
 - Acetabulum
 - Femoral Neck
 - Femoral Head
 - Greater & Lesser Trochanter
 - Intertrochanteric line
-



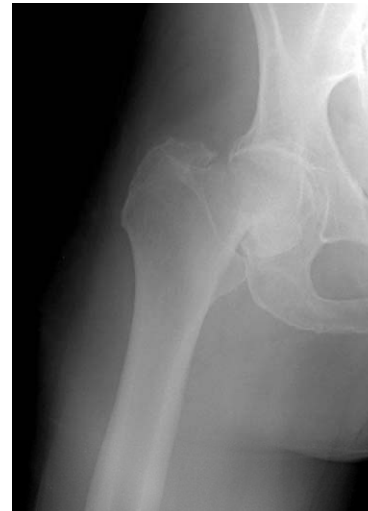Hip Anatomy

- Soft Tissue
 - Iliopsoas Tendon
 - Adductor Origin
 - Trochanteric Bursa
 - Labrum
-

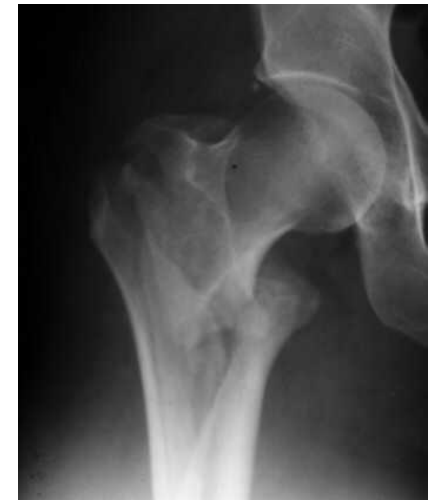

Bony Problems

- Fracture (Trauma)
 - Femoral Neck
 - Intertrochanteric



Femoral neck



Intertrochanteric



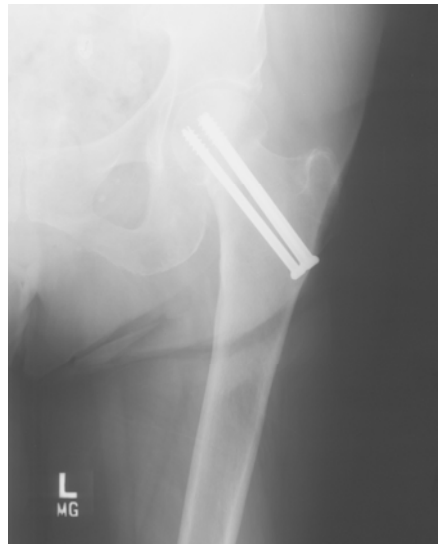Stress Fracture

- Femoral Neck
 - Pubis
-

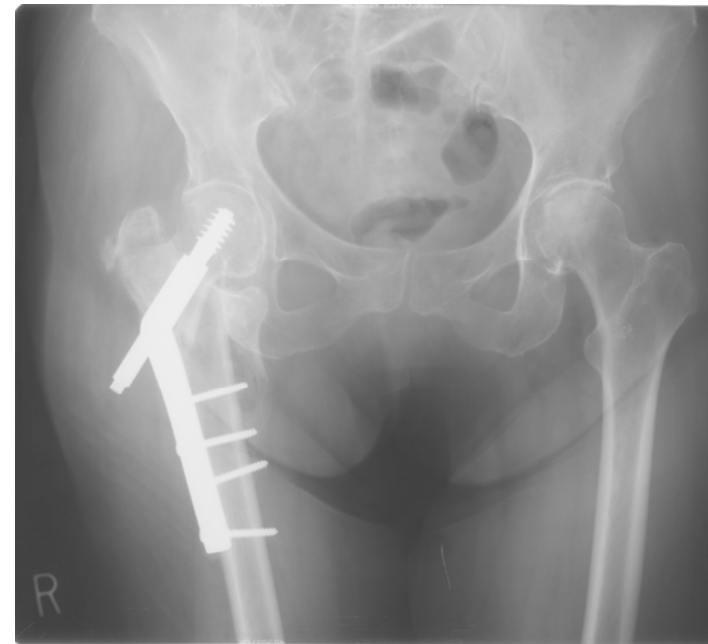


Femoral Neck Fracture

- Treatment
 - Internal Fixation



Hip Pinned

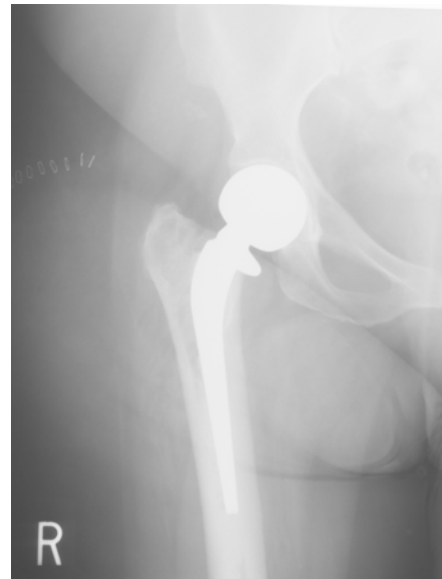

Compression Screw



Femoral Neck Fracture

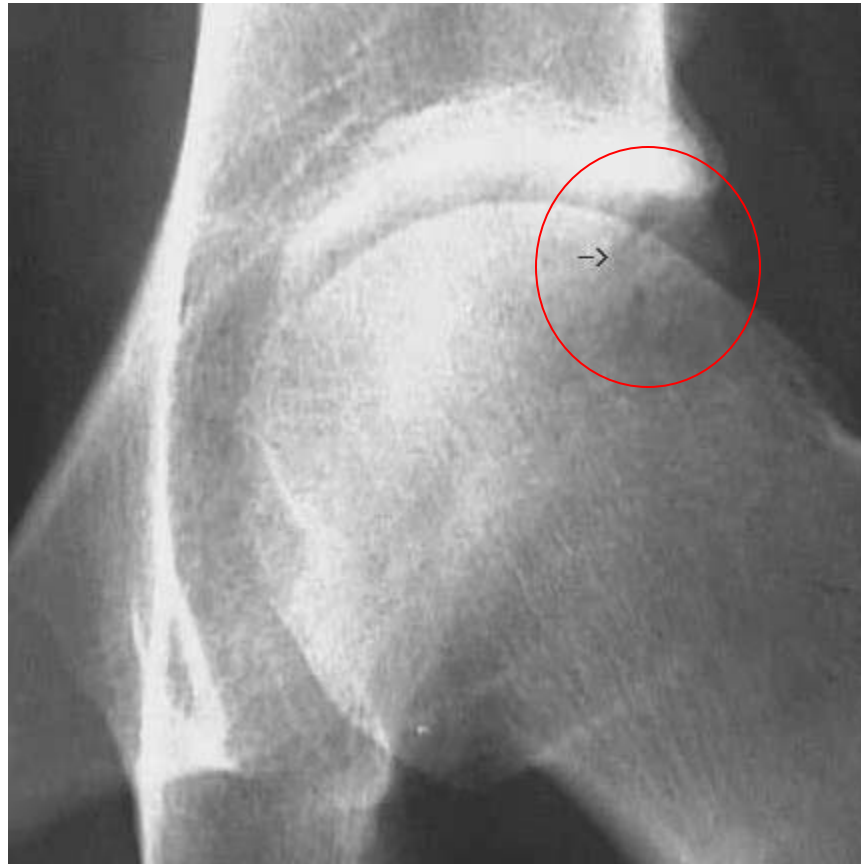- Treatment (cont.)
 - Hemiarthroplasty
 - Total Hip



Hemiarthroplasty

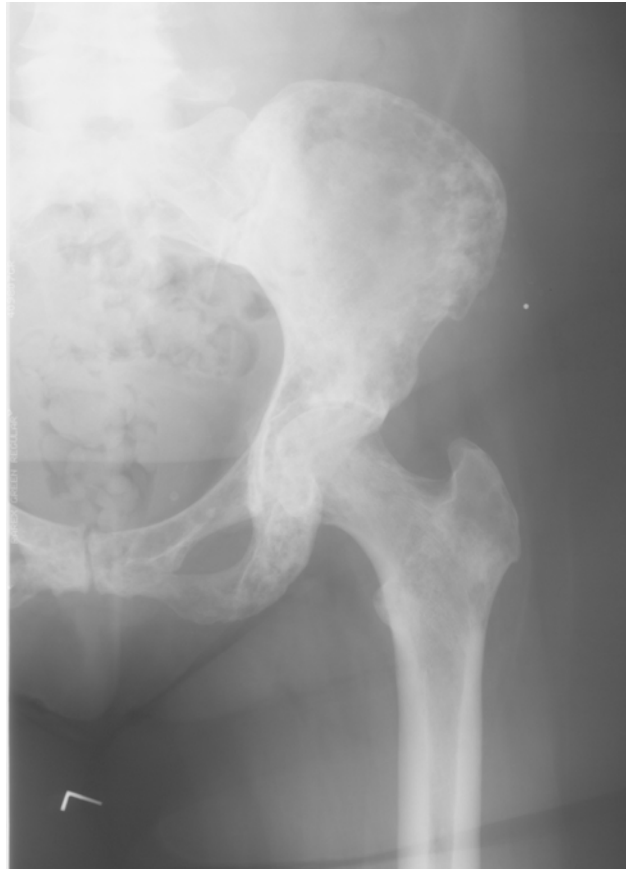

Acetabular Fracture





Hip Arthritis





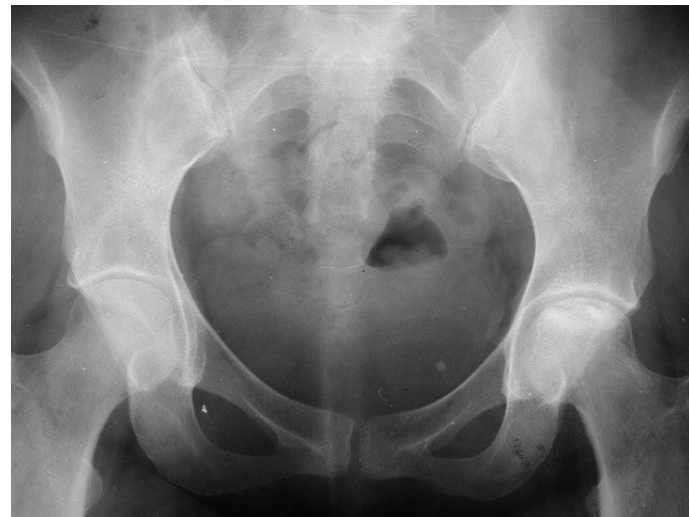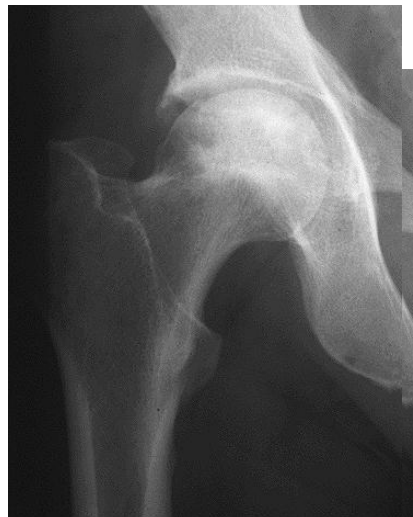Hip Arthritis

- Treatment of Hip Arthritis
 - Non-Steroid Anti-Inflammatory Drug
 - Steroid Injection
 - Total Hip Replacement
-



Avascular Necrosis of Hip (AVN)

- Post-Traumatic
- Steroid Use
- Idiopathic (No Known Cause)





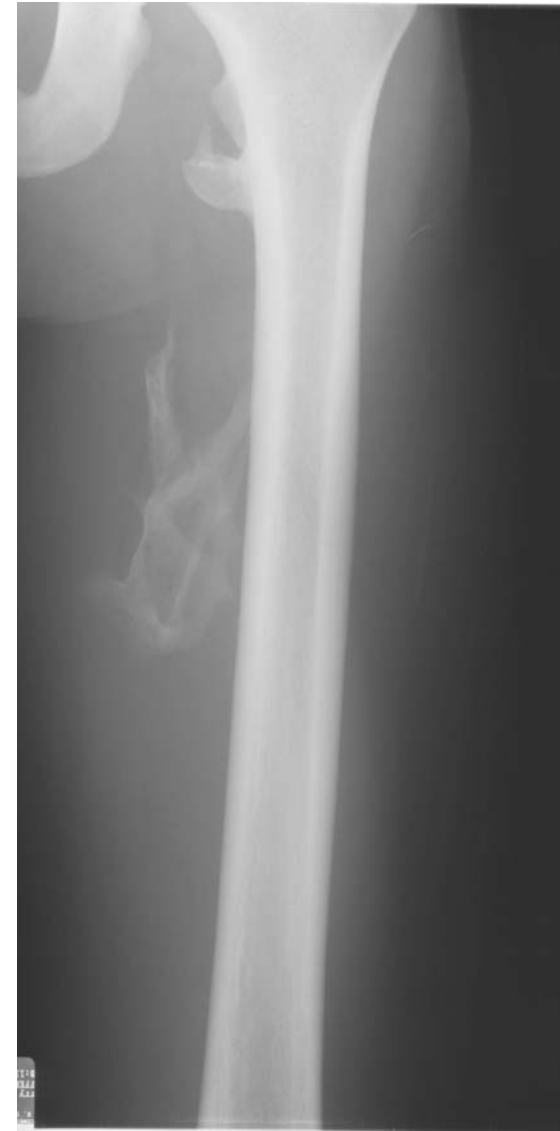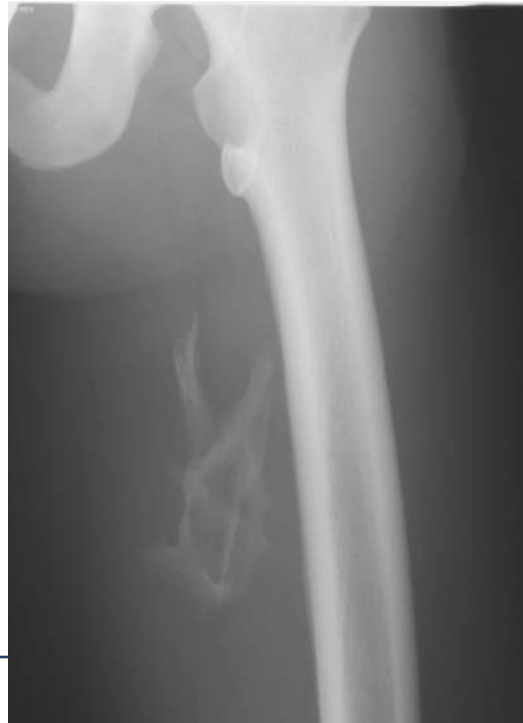AVN


- Treatment of AVN
 - Rest
 - Core Bone Grafts
 - Hemiarthroplasty
 - Total Hip Replacement
-



Muscle Injuries

- Adductor Strain
- Ectopic Bone





Bursitis

- Ischial Bursitis
 - Trochanteric Bursitis
 - Iliopsoas Bursitis
-



Treatment of Bursitis

- Non-Steroid Anti-Inflammatory Drug
 - Steroid Injection
-



Labral Tears

- Diagnosis – MR Arthrogram
 - Treatment – Arthroscopy
-



Diagnosis of Hip Disorder

- Location of Pain
 - Groin
 - Anterior Thigh
 - Knee
 - Quad Atrophy
 - Flexion Contraction
 - Loss of Range of Motion
 - Trendelenburg Gait
-



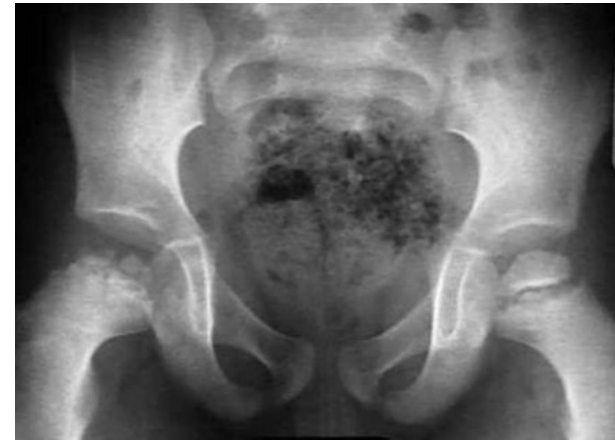Typical Hip “Errors”

- Thigh and Knee Pain
 - Buttock Pain
 - Missed Femoral Neck Fracture
-

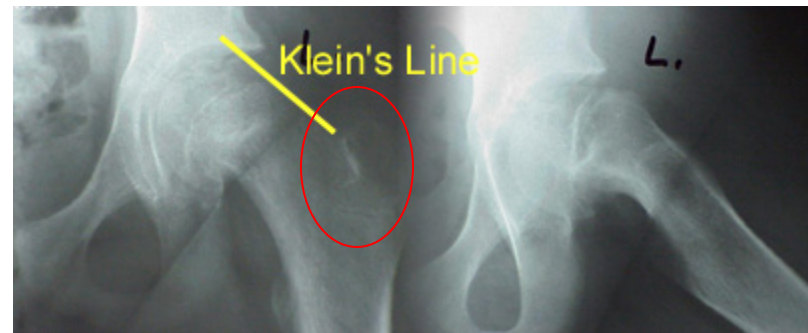



Pediatric Hip Problems

- Perthes Disease



- Slipped Capital Femoral Epiphysis (SCFE)






Hip Pointer

- Bone Bruise





ANKLES





Ankle Anatomy - Bone

- Ankle Mortise
 - Tibia, Fibula, Talus
 - Subtalar Joint
-



Ankle Anatomy – Soft Tissue

- Deltoid Ligament
 - Lateral Ligament Complex
 - Anterior Talo-Fibula
 - Fibula-Calcaneal
 - Post Talo-Fibula
 - Syndesmotic Ligaments
-



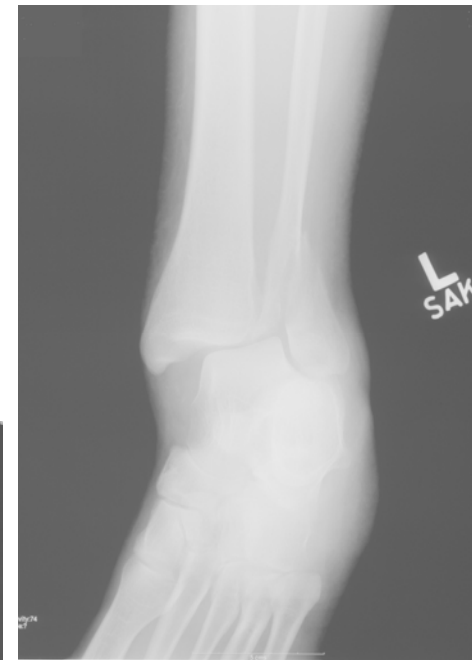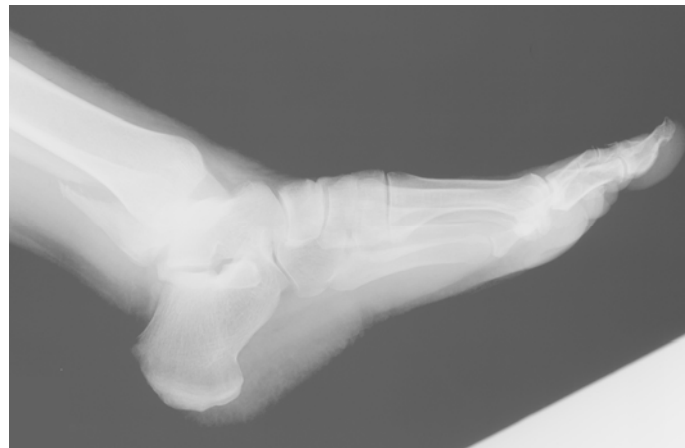
Ankle Anatomy – Soft Tissue

- Post Tibial Tendon
 - Peroneal Tendons
 - Achilles Tendon
-



Bony Problems – Fractures

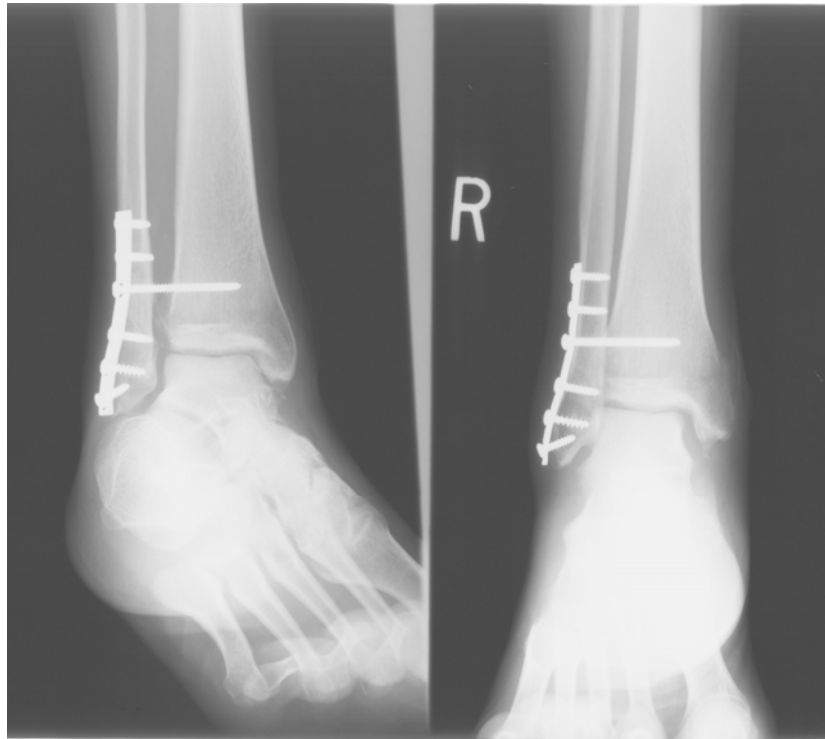
- Lateral Malleolus
- Bimalleola
- Trimalleola
- Pilon Fracture





Treatment

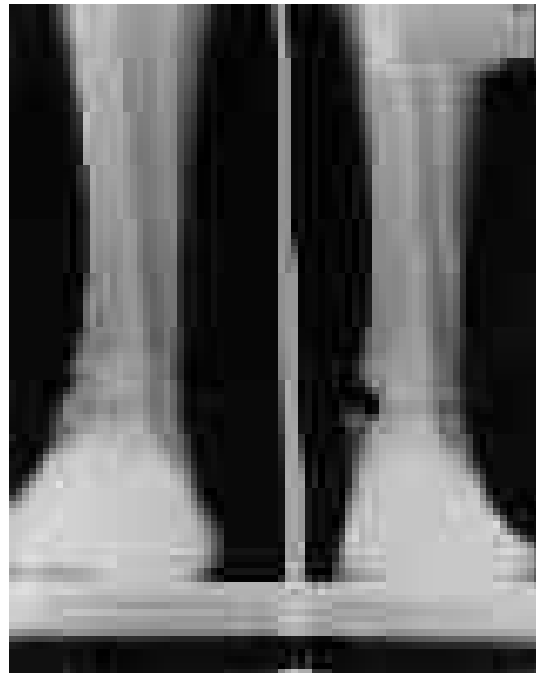
- Open Reduction Internal Fixation (ORIF)





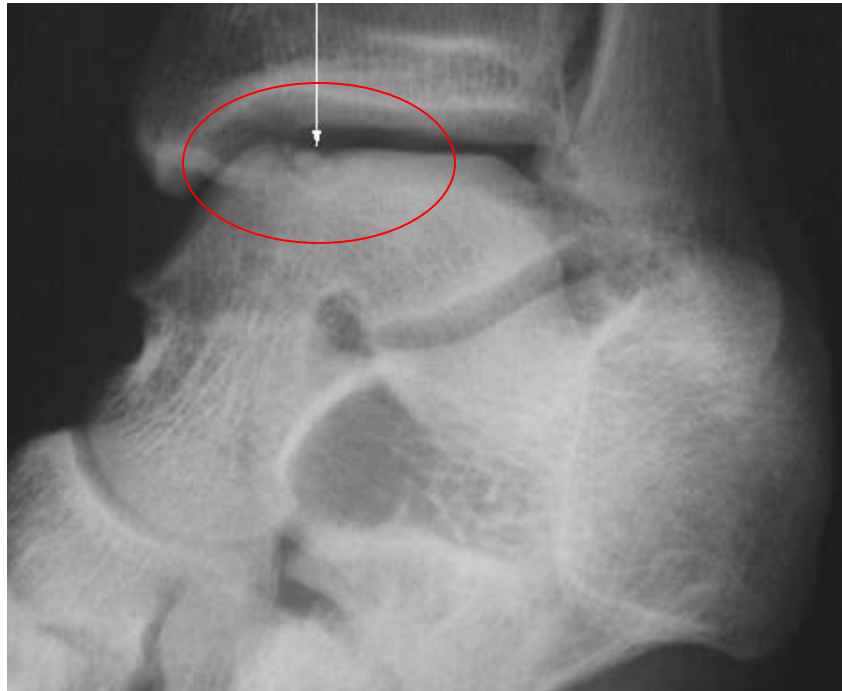Stress Fractures

- Medial Malleolus
- Fibula





Osteochondritis Dissecans of Talus (OCD)





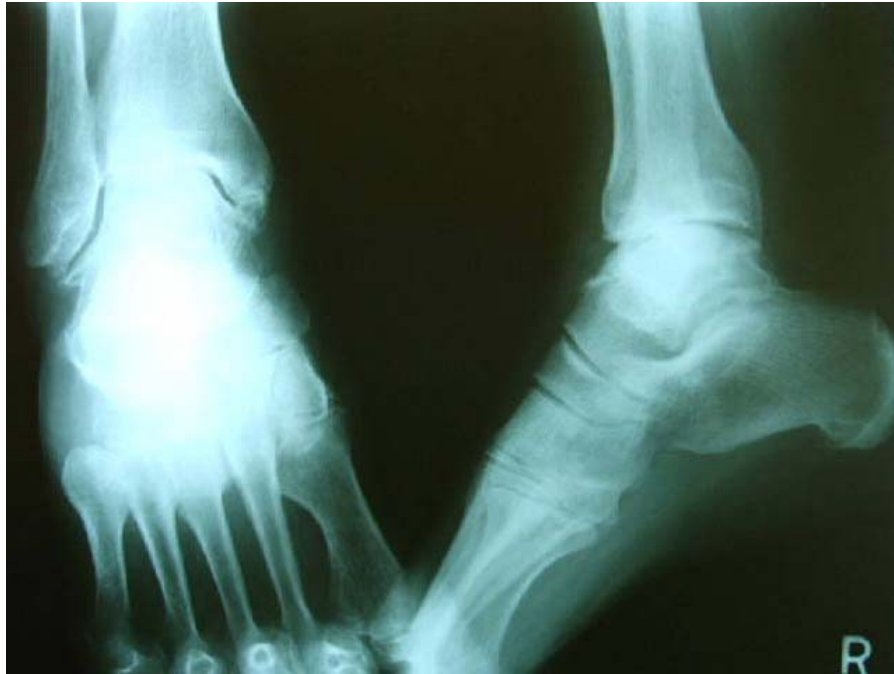Treatment of OCD

- Arthroscopy
 - Debridement
 - Microfracture
 - OATS (Osteo Autologous Transplantation)
-

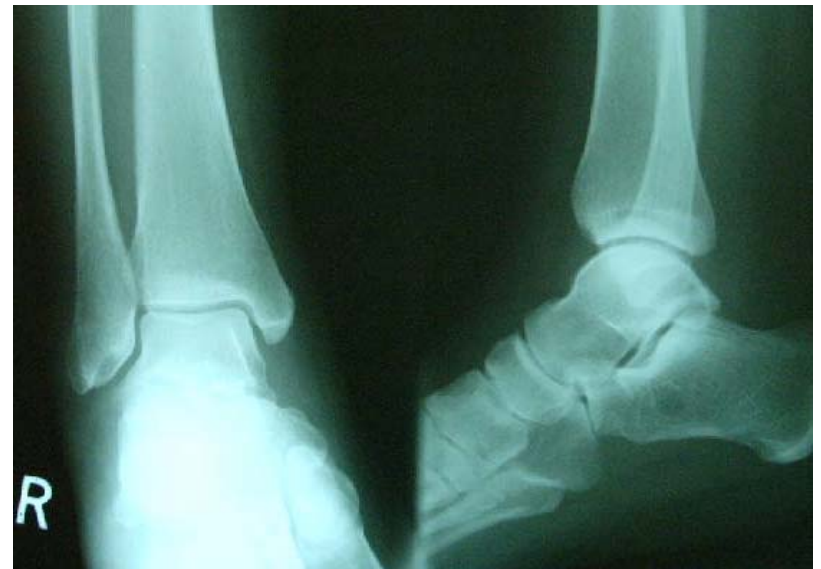

Ankle Arthritis

Arthritic ankle

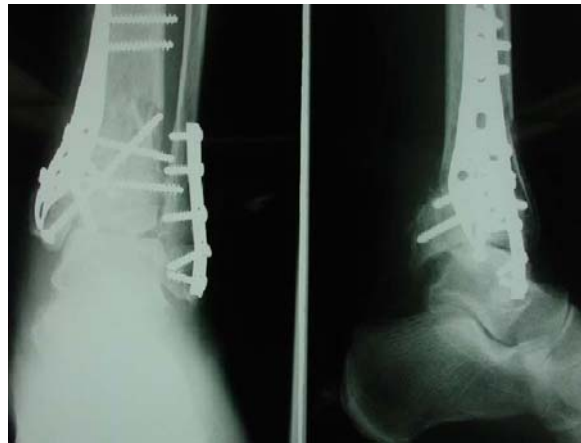

Normal ankle

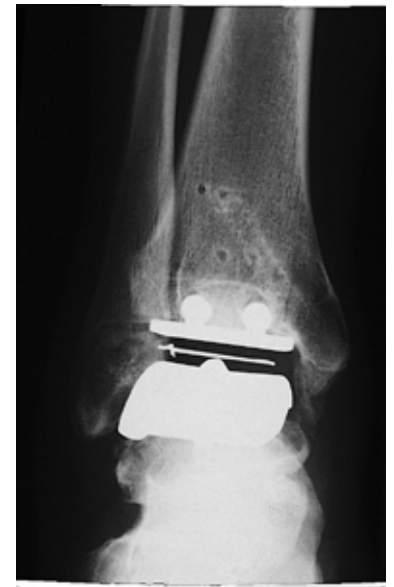

Ankle Arthritis

- Treatment of Ankle Arthritis
 - Non-Steroid Anti-Inflammatory Drug
 - Steroid Injections
 - Arthroscopy
 - Fusion
 - Total Ankle



Fusion



Total Ankle



Ankle Sprain Types

- Severity (I, II, III)
 - Tendons
 - Lateral
 - Deltoid
 - Syndesmotic
-




Ankle Sprain

- Treatment of Ankle Sprain
 - Rest, Ice
 - Brace
 - Physical Therapy
-



Chronic Instability

- Physical Therapy
 - Ligament Reconstruction Surgery
-



Tendon Problems

- Achilles
 - Posterior Tibial
 - Peroneal
-



Achilles Rupture

- Thompson Test
-

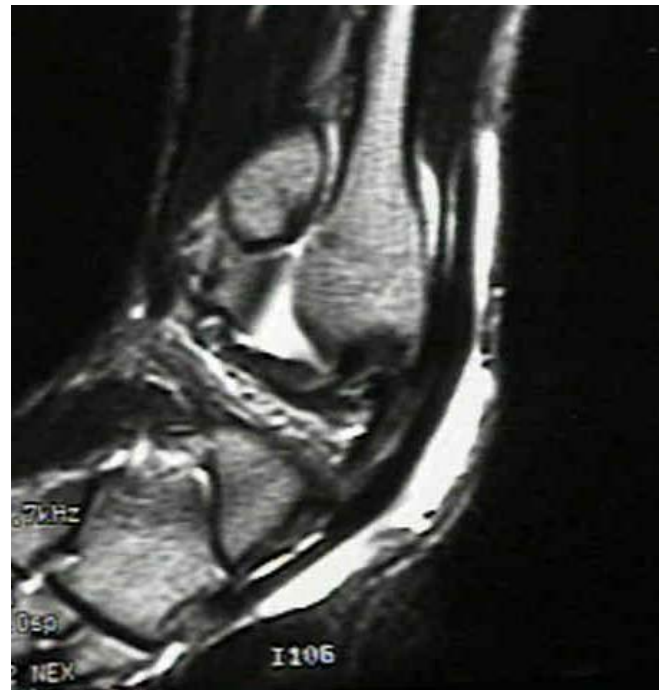


Posterior Tibial Tendon Problems

- Tendonitis
 - Rupture
 - Pes Planus (Flat Foot)
-



Dislocation Peroneal Tendon





Hips and Ankles

Presented for educational purposes by:

Querrey  *Harrow*

Featured Speaker:

John A. Hefferon, M.D.

Co-Medical Director, The Neurologic & Orthopedic Institute of Chicago
